

Intrastromal corneal ring segment targets nipple keratoconus

Option allows surgeons to effectively address cone morphology without resorting to a corneal graft.

by **Dominique Pietrini, MD, and Tony Guedj, OD, ORTHO**



Intrastromal corneal ring segments are a proven treatment option for contact lens-intolerant keratoconus patients.

The objective of intrastromal corneal ring segments (ICRS) implantation is to regularize corneal surface distortions, thus reducing low- and high-order optical aberrations, improving uncorrected distance visual acuity and corrected distance visual acuity, reducing the refractive error and improving contact lens tolerance.

We recently started using the new Keraring 355° (Mediphacos), which is an extension of the Keraring product line. It has a 6-mm optical zone, 355° arc length and variable thicknesses of 200 μm or 300 μm . The main indication for use of this corneal implant is in cases of nipple-type keratoconus, which comprises a small, near-central ectasia that is 5 mm or less in diameter. Often, there is an elevated fibroblastic nodule at the apex of the cone, hence lending the condition the moniker of “nipple” type.

We have routinely treated keratoconus with ICRS implantation for more than 10 years, using different types of ICRS. In our experience, nipple cones do not respond as well to classic ICRS designs as do decentered oval cones. Therefore, the Keraring 355° fills an important gap in our treatment armamentarium and is a valuable option for improving quality of vision in patients with nipple-type keratoconus.

New implantation technique

The implantation procedure for the Keraring 355° is different from that used for other ICRS. Due to its long arc length, it can be technically

challenging to implant this ring in a narrow stromal tunnel. Therefore, we have been using a femtosecond laser (iFS, Abbott Medical Optics) to create an 8-mm diameter pocket at a depth of 300 μm with a 2-mm superior incision. We use a spatula to inspect the pocket to make sure there are no tissue bridges left. The ICRS is easily guided through the small incision into the stromal pocket and centered on the visual axis, which is marked beforehand.

Overall, the creation of the pocket with a femtosecond laser is a simple procedure and is not associated with a learning curve. The small, 2-mm vertical incision ensures fast healing and does not compromise the corneal biomechanics. However, one limitation of the pocket technique is that the pocket must be placed at a depth of 300 μm , which in turn requires a minimum corneal thickness of 400 μm at the thinnest point. More superficial pockets will increase the chances of ICERS extrusion, whereas deeper pockets may compromise the visual result because current femtosecond lasers usually create a rougher stromal interface when the lamellar dissection is programmed deeper than 300 μm . These limitations are enticing some surgeons to use the tunnel technique for implanting the Keraring 355°, and we are looking forward to their reports in the near future.


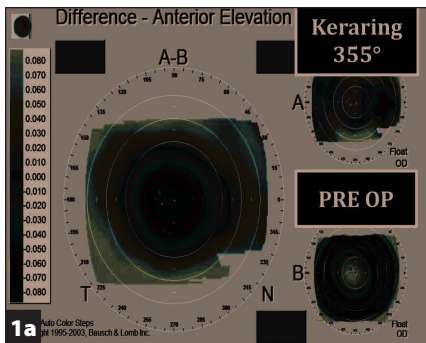
Case study

We implanted the Keraring 355° bilaterally in a 32-year-old woman with central nipple-type keratoconus. In her right eye, she had a central pachymetry of 423 μm , keratometry of K1: 51.8 D, K2: 53.2 D, K2 axis: 134°, uncorrected distance visual acuity of 0.1, corrected distance visual acuity of 0.6, astigmatism of 1.4 D, and primarily myopic refraction of $-7.50 -1.50 \times 110^\circ$. The preoperative exam was similar in her left eye, where she had a central pachymetry of 412 μm , keratometry of K1: 52.8 D, K2: 55.7 D, K2 axis: 44°, uncorrected visual acuity of counting fingers, corrected distance visual acuity of 0.4, astigmatism of 2.9 D, and myopic refraction of $-8.75 -2.50 \times 60^\circ$.

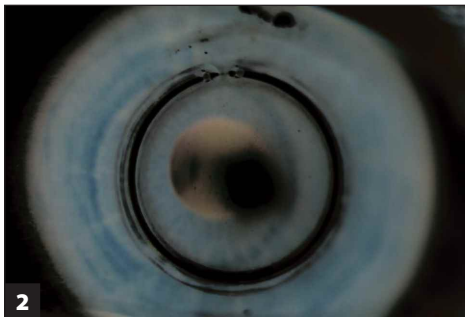
The results from the procedure were impressive, as the patient not only achieved a correction of myopia, but also showed improved quality of vision due to marked corneal flattening and reduction in spherical aberration. Five months postoperatively, the patient's refraction was $+0.50 -1.00 \times 70^\circ$ in the right eye and $+0.50 -1.00 \times 80^\circ$ in the left eye. In her right eye, uncorrected distance visual acuity improved to 0.6, and she gained one line of corrected distance visual acuity. In the left eye, she achieved an uncorrected distance visual acuity of 0.5 and gained two lines of corrected distance visual acuity. Differential maps showed an 80- μm reduction in anterior elevation and considerable flattening of the cornea, up to 15 D, without inducing high amounts of astigmatism (Figure 1).

Choosing the appropriate ICRS

Each keratoconic cornea is unique and requires an individual assessment to identify the most appropriate ICRS size and location and



Differential maps of the right eye pre- and postoperation showing (a) an 80- μm reduction in anterior elevation and (b) a reduction in anterior curvature.



The Keraring 355° implanted in the patient's eye.

on the type of keratoconus, keratometry values, astigmatism, refraction and asphericity. The wide range of sizes available in the Keraring platform provides a valuable tool for customizing the corneal remodeling effect for each patient. With the recent introduction of the Keraring 355°, there are now 42 different ICRS size options from which to choose.

The segments are available in thicknesses ranging from 150 μm to 350 μm in 50 μm steps, variable arc lengths (90°, 120°, 160°, 210° and 355°), and optical zones of 5 mm, 5.5 mm and 6 mm. Depending on the case, one or two ICRS segments of the same or different sizes may be implanted. The implant is delivered with one ring segment per box so the surgeon can mix and match the sizes and number of segments implanted as desired.

The Keraring 355° is a new option for ophthalmologists treating keratoconus. It is specifically designed for nipple-type keratoconus, and for the first time allows surgeons to effectively address this cone morphology without resorting to a corneal graft.



Dominique Pietrini, MD, and Tony Guedj, OD, ORTHO, can be reached at Centre de la Cornée et du k eratoc one, Paris, France; +33-1-45-63-06-68; email: docteurpietrini@gmail.com, tony.guedj@yahoo.fr.

Disclosures: Pietrini and Guedj have no relevant financial disclosures.

to achieve good outcomes. The ICRS diameter, thickness, arc length and implantation meridian are important parameters to consider.

We select the implant specification and location by using the manufacturer's nomogram, which is based